

**NEW**

# HyFlex™ Remover

The essential piece for your retreatment

## One file to remove the canal obturation

Remover is a new addition to the Hyflex range for the removal of old obturation material, integrating the latest generation of cross-sectioning with 3 cutting edges and heat treatment.

## Just one file for the removal of old material

You only need one instrument to remove the Gutta-Percha in the canal.

## Efficient without solvent use

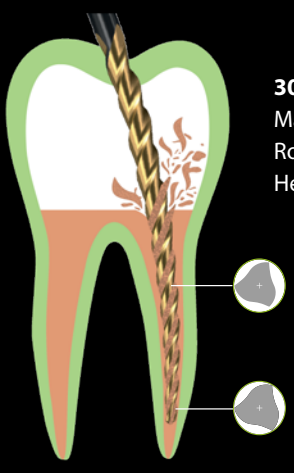

The only file on the market clinically qualified to be used without solvent.

## Safe instrument

Due to its design, its non-cutting tip and its protocol, REMOVER avoids ledges and respects the root canal anatomy and while being effective.

## Reduce the learning time

Remover fits perfectly into an existing retreatment procedure without requiring a change in approach. It's an essential tool for retreatment and can be used with conventional shaping files.



**30/.07**  
 Maximum torque : **2.5 N.cm**  
 Rotation speed : **400-800 rpm**  
 Heat treatment : **C.Wire**

### HyFlex™ Remover

Blister pack of 5 instruments - Sterile

- B5 HyFlex Remover L19 n30 7% REF 60023649
- B5 HyFlex Remover L23 n30 7% REF 60023648



REMOVER FILE  
 IN ACTION



# Remover: The ultimate solution for removing gutta-percha

Authors: Prof. Walid Nehme, Dr. Jean-Philippe Mallet, Dr. Bérenger Soulages, Dr. Mathilde Michel, Dr. Franck Diemer

## Introduction

Endodontic retreatment is generally considered the first choice option when failure of an initial treatment occurs. The presence of bacteria and their by-products embedded in the failing obturation material and in canal intricacies is often linked to the loss of integrity of the hermetic seal of the initial filling, leading to the spread of post-treatment disease. It is therefore of utmost importance to remove all the root canal filling material effectively prior to negotiating the canals to their full extent.

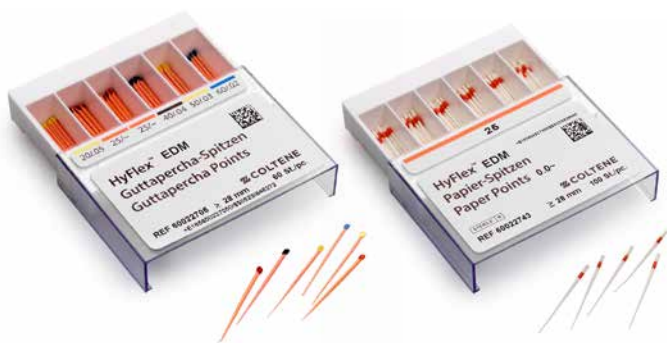Several techniques and instruments have been proposed to remove gutta-percha, including hand files or mechanical instruments or a combination of both. Nowadays, manual files are generally regarded as time-consuming and the current trend is towards more efficient tools, such as rotary instruments. Since the beginning of the 2000s, specific endodontic files have been designed to improve the removal of gutta-percha. R-ENDO (COLTENE Micro-Mega) was the first sequence available, followed rapidly by ProTaper

Universal Retreatment (Dentsply Sirona). These two sequences have three files and are used with the crown down technique. Later, many systems were developed by several companies, such as D-Race from FKG Dentaire, Mtwo R from VDW and Endo ReStart from Komet, and these presented different profiles, cross sections and recommended techniques.

Moreover, several developments have marked the last two decades and changed the way we practise endodontics, among them the single-file concept and the heat treatment process. The response to the increasing demand by dental clinicians for a simplified process led to new shaping systems with a single file. The aim was to replace multiple-file systems in the initial canal treatment, but it was later recommended for retreatment too.

The advent of new manufacturing processes, such as surface finishing or heat treatment, aiming to upgrade the mechanical performance of nickel-titanium (NiTi) files led to new file systems that are more flexible and more resistant to cyclic fatigue.

### HyFlex™ EDM Paper and Gutta-Percha Points



HyFlex EDM Paper and Guttapercha points selection

Size / tape	Paper points 100 pcs	Guttapercha points 60 pcs
20 / .05	60022742	60022706
OneFile 25/~	60022743	60022707
40 / .04	60022676	60022708
50 / .03	60022741	60022709
60 / .02	60022740	60022710
Assortment 20/.05 - 60/.02	60022744	60022705

### HyFlex™ CM GuttaPercha Points Greater Taper



HyFlex CM Guttapercha points Greater Taper selection

.04 #20	60 pcs	60022689
.06 #30	60 pcs	60022699
.06 #45	60 pcs	60022702
.04 #60	60 pcs	60022696
.04 #20-45	60 pcs	60022703
.06 #20-45	100 pcs	60022704

The Remover (COLTENE) has benefited from all these technological advances and concepts for removal of obturation material.

**Removal of different sealers**

A retreatment file is supposed to go through the deficient obturation material and remove it from the canal. This material generally includes a core material (gutta-percha) sealed to the canal walls with a fine film of endodontic sealer. Different types of sealers have been used over the years. Historically, zinc oxide eugenol sealers were the first, but many others have been proposed to improve different properties of the sealer. These include resin-based sealers to improve the hermetic seal and adhesion to the canal walls; silicone-based sealers, which are well tolerated by tissue and have low water resorption; epoxy resin-based sealers for the possibility of adhesion to dentine and lower rates of water solubility; sealers based on mineral trioxide aggregate which have a predilection towards mineralization; calcium silicate sealers, commonly referred to as “bioceramics” owing their excellent biological properties; and calcium phosphate and calcium-enriched mixture sealers with the potential to promote bone regeneration and induce cementogenesis.

The purpose of such an instrument would therefore be to remove the initial obturation material, paving the way for access to the non-instrumented area with conventional NiTi instruments and thus proper reshaping of the canal space. The Remover has benefitted from state-of-the-art technology in material processing and long experience in file design and has been developed by COLTENE in response to the dental community’s increasing demand for a means of safe, simple and swift removal of gutta-percha in retreatment procedures.

This unique instrument (Fig. 1) boasts numerous specifications and technical characteristics, including:

- a non-cutting tip of 30/100 mm, allowing safe use in curved canals (Fig. 2);
- a variable triple-helix cross section, symmetrical in the first 3 mm then asymmetrical towards the shaft;
- a 7 % taper limited to the first 10 mm and followed by a 0 % taper towards the shaft in order to preserve periradicular dentine;
- a proprietary thermomechanical process called C-wire, entailing electropolishing and heat treatment and increasing flexibility and cyclic fatigue resistance.

**Preparation – technique for use**

Once the access cavity has been reopened canal entrances located and gutta-percha confirmed to be the canal filling material, an orifice modifier (HyFlex EDM, COLTENE; or One Flare, COLTENE MicroMega) can be introduced into the gutta-percha for 2–3 mm on continuous rotation at a speed of 400–800 rpm. This instrument is used to create a pilot hole, guide the engagement of the Remover inside the gutta-percha and achieve a straighter access. The Remover should be used in continuous rotation at 400–800 rpm and 3.0–3.5 Ncm with very light apical guidance. The 19 mm Remover is introduced into the opening created by the opener and moved in an apical direction over a distance of 2–3 mm until slight resistance to inward movement is felt, and then it should be pulled out while

HyFlex™ CM and EDM Paper Points

**HyFlex CM Paper Points, drawer box**

Files Size	HyFlex CM Paper Points, 100 pcs
15/.04	60022671
20/.04	60022672
25/.04	60022673
30/.04	60022674
35/.04	60022675
40/.04	60022676
45/.04	60022677
50/.04	60022678
60/.04	60022679
Assortment 20-45 /.04	60022680
20/.06	60022682
25/.06	60022683
30/.06	60022684
35/.06	60022685
40/.06	60022686
45/.06	60022687
Assortment 20-45 /.06	60022688



**HyFlex EDM Paper Points, drawer box**

Files Size	HyFlex EDM Paper Points, 100 pcs
20/.05	60022742
OneFile 25/~	60022743
40/.04	60022676
50/.03	60022741
60/.02	60022740
Assortment 20/.05 - 60/.02	60022744



Figure 1




Figure 2

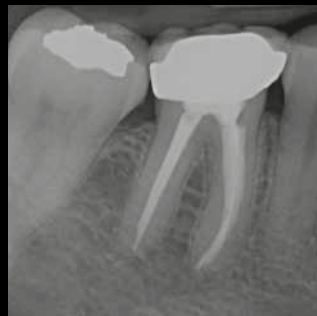

Figure 3g

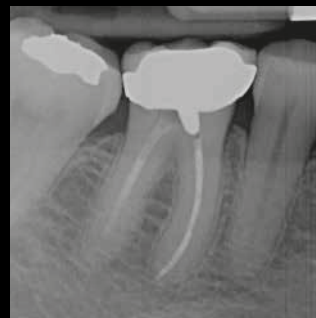

Figure 3a

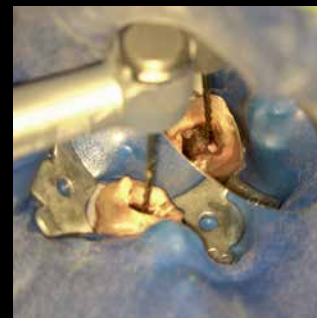

Figure 3b

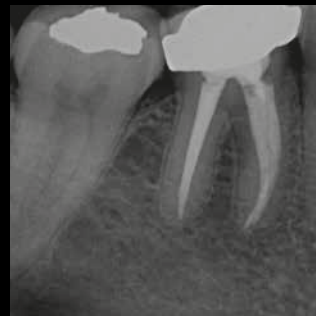

Figure 3h

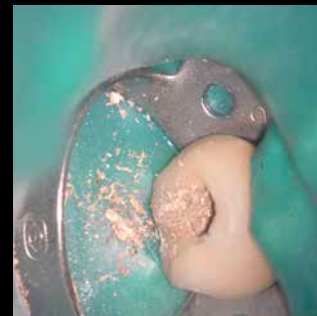

Figure 4

leaning on selective canal walls to dislodge all the gutta-percha. In general, all the filling material can be removed with a series of three to four in and out motions in a downwards apical direction (Figs. 3a–h). The removed material usually comes out in small shavings (Fig. 4), but also as a mass of gutta-percha. The removal of the filling material must be followed by copious irrigation in order to wash away all the debris and sealer residue. Once all the filling material has been removed, scouting and glide path creation can be carried out using manual or NiTi files. Standard reshaping instruments such as 2Shape, One Curve (COLTENE MicroMega), or HyFlex CM or EDM (COLTENE) can now be used to clean and shape the non-filled canal space and to ensure the smooth transition between previously filled and unfilled portions. Clinicians must keep in mind that a continuously tapered preparation is essential for 3D obturation.

When clinical and radiographic diagnoses indicate retreatment of a case showing obturation material reaching the apical area, the clinician is advised to limit the use of the Remover to 2 mm short of the estimated working length. The objective is to prevent potential overextension of filling material into the periapical area. The filling material in the last 2 mm can be carefully and securely removed with manual files. Once all previous material has been removed, the cleaning and shaping can be undertaken using standard NiTi shaping instruments (Figs. 5a & b).

#### Flexible retreatment

The Remover is available in two lengths: 19 and 23 mm. A large number of cases can be addressed with 19 mm files. If the 19 mm Remover does not reach the full extent of the filling material, the 23 mm file can be used to make up for the missing millimetres.

This new instrument, specifically designed for endodontic retreatments, embodies the current concepts in endodontics and uses the most recent advances in technology (asymmetry, electropolishing and heat treatment). The diameter of the wire of the Remover is only 1 mm, which makes it smaller than that of the majority of reshaping or retreatment instruments. Moreover, it allows for minimally invasive removal of filling material while ensuring increased blade flexibility.

It is a single-use instrument; however, removing the filling material from two teeth in the same patient is possible. In this case, the

instrument should be carefully inspected after use and discarded when unwinding occurs.

#### Conclusion

This instrument allows the removal of gutta-percha canal filling swiftly, thoroughly and safely, transforming this difficult procedure into a more predictable and easier task. Finishing the preparation size and taper varies according to the anatomy of each clinical case. Clinicians should keep in mind that the size and taper of the selected final shaping file should allow a total elimination of the filling material and the cleaning and shaping of the apical third. This step should obviously be accompanied by abundant irrigation and activation of the irrigants using specifically designed ultrasonic generators and tips such as EndoUltra (COLTENE MicroMega). Thorough cleaning and shaping complete the retreatment procedure, facilitate the 3D obturation and promote a successful root canal therapy outcome.

→ **Fig. 1:** Remover for the HyFlex and MicroMega file systems (© Coltène/Whaledent).

→ **Fig. 2:** Scanning electron microscope image of the tip of the Remover (© Franck Diemer).

→ **Figs. 3a–h:** Retreatment of a tooth #46 pre-op radiograph (3a); the Remover is positioned at the entrance to the mesiolingual canal (3b) and is progressively advancing into the gutta-percha (3c); pathway created by the Remover after its first central advance into the gutta-percha (3d); mesial canals after shaping and mechanical irrigation (2Shape TS2 and F35 finishing files, COLTENE MicroMega) (3e); pre-op radiograph to check the master cones (3f); post-op radiograph centred (3g); post-op radiograph offset (3h) (© Jean-Philippe Mallet).

→ **Fig. 4:** Photograph of the shavings created by the Remover (© Jean-Philippe Mallet).

→ **Figs. 5a & b:** Teeth #21 and #22 requiring retreatment: pre-op radiograph (5a); post-op radiograph (5b) (© Walid Nehme).

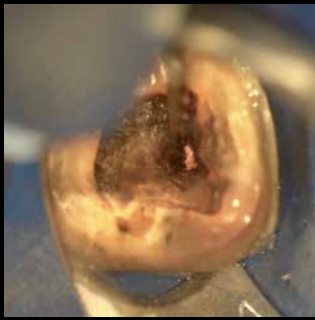


Figure 3c

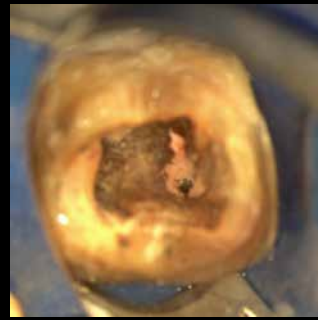


Figure 3d

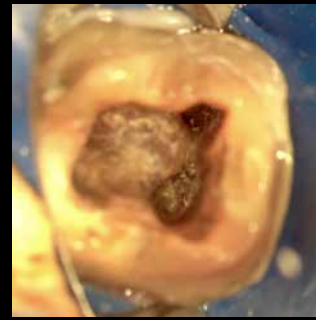


Figure 3e

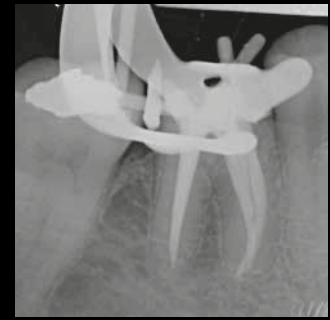


Figure 3f

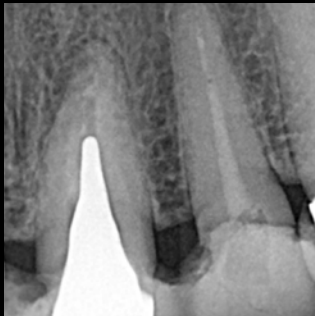

Figure 5a

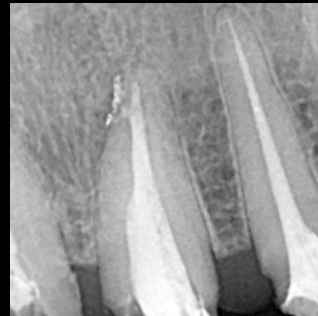


Figure 5b

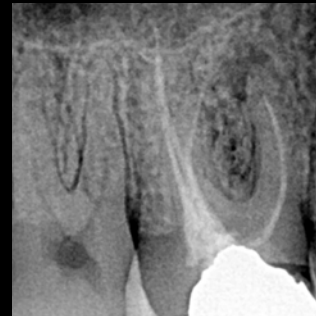

Figure 6a

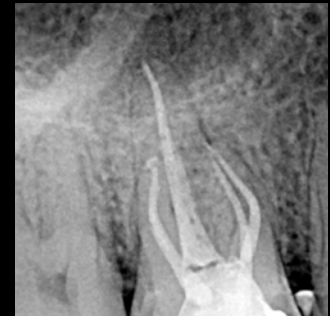

Figure 6b

→ **Figs. 6a & b:** Pre-op radiograph of a maxillary first molar presenting with periapical periodontitis with a forgotten canal in the mesiovestibular root (6a). Post-op radiograph after filling removal with the Remover, cleaning and shaping with the 2Shape and apical finishing with the F40 (0.40 tip and 4 % taper) in palatal and disto-buccal canals (6b) (© Walid Nehme).

#### About the Author:

Prof. Walid Nehme is a clinical professor in the department of endodontics of Saint Joseph University of Beirut in Lebanon, where he received his DDS in 1988 and MSc in 1994. His academic activities lie in undergraduate and postgraduate education in endodontics and focus on clinical training and practice and supervision of research projects. He runs postgraduate endodontic courses and hands-on courses in the Middle East, Africa, Europe and Canada. Prof. Nehme works in a referral-based practice limited to endodontics in Beirut and Abu Dhabi in the UAE. He is an analyst and opinion leader for clinical trials for endodontic manufacturers and has contributed to the development of new files and devices in endodontics. He has published scientific and clinical articles in peer-reviewed journals nationally and internationally on such subjects as root canal anatomy, instrumentation techniques, NiTi files, irrigation procedures, obturation and retreatment. He is a fellow of the International College of Dentists, an international member of the American Association of Endodontists, a council member of the Asian Pacific Endodontic Confederation, a founder member and a past president of the Arab Endodontic Society, and a past president of the Lebanese Society of Endodontology.



#### Contact:

Prof. Walid Nehme  
Space 2 Center  
New Jdeiden Street  
Beirut, Lebanon  
walidnehmeendo@gmail.com

#### More information at:

<https://remover.coltene.com>

#### References

- Bergenholtz, G. "Assessment of Treatment Failure in Endodontic Therapy". *Journal of Oral Rehabilitation* 43, no. 10 (October 2016): 753–58.
- Kerekes K, Tronstad L. Long-term results of endodontic treatment performed with a standardized technique. *J Endod.* 1979; 5:83–90.
- Alharmoodi R, Al-Salehi S. "Assessment of the Quality of Endodontic Retreatment and Changes in Periapical Status on a Postgraduate Endodontic Clinic". *Journal of Dentistry* 92 (January 2020): 103261.
- Covello F, Franco V, Schiavetti R, Clementini M, Mannocci A, Ottria L, Costacurta M. Prevalence of apical periodontitis and quality of endodontic treatment in an Italian adult population. *Oral & Implantology* 3(4) (2010): 9–14
- Al-Omari M.A., Hazaa A., Haddad F. Frequency and distribution of root filled teeth and apical periodontitis in a Jordanian subpopulation. *Oral Surgery Oral Medicine Oral Pathology Oral Radiology & Endodontics* 111(1) (2011): e59–65.
- K.M. Barrieshi-Nusair, M.A. Al-Omari, A.S. Al-Hiyasat, Radiographic technical quality of root canal treatment performed by dental students at the Dental Teaching Center in Jordan. *Journal of Dentistry* 32(4) (2004): 301–7.
- Friedman S, Mor C. The success of endodontic therapy—healing and functionality. *J Calif Dent Assoc.* 2004;32:493–503.
- Bender IB, Seltzer S, Soltanoff W. Endodontic success are appraisal of criteria. *Oral Surg Oral Med Oral Pathol.* 1966; 22: 790–802.
- SBU. Methods of diagnosis and treatment in endodontics. Stockholm: Stockholm: Swedish Council on Health Technology Assessment (SBU), 2010. SBU report no. 203. <http://www.sbu.se/upload/Publikationer/>, accessed 13 August 2010.
- Möller ÅJ, Fabricius L, Dahlén G, Sundqvist G, Happonen RP. Apical periodontitis development and bacterial response to endodontic treatment. Experimental root canal infections in monkeys with selected bacterial strains. *Eur J Oral Sci.* 2004; 112: 207–215.
- Bicego-Pereira EC, Barbosa-Ribeiro M, de-Jesus-Soares A, Zaia AA, Ferraz CCR, Almeida JFA, Marciano MA, Feres M, Gomes BPFA. "Evaluation of the Presence of Microorganisms from Root Canal of Teeth Submitted to Retreatment Due to Prosthetic Reasons and without Evidence of Apical Periodontitis". *Clinical Oral Investigations*, 20 Jan 2020. [epub ahead of print]
- Shetty K, Habib VA, Shetty SV, Khed JN, Prabhu VD (2015) An assessment of coronal leakage of permanent filling materials in endodontically treated teeth: an in vitro study. *J Pharm Bioallied Sci* 7(Suppl 2): S607–S611.
- Yamaguchi M, Noiri Y, Itoh H, Komichi S, Yagi K, Uemura R, Naruse H, Matsui S, Kuriki N, Hayashi M, Ebisu S. "Factors That Cause Endodontic Failures in General Practices in Japan". *BMC Oral Health* 18, no. 1 (December 2018): 70.
- Fabricius L, Dahlén G, Sundqvist G, Happonen RP, Möller ÅJ. Influence of residual bacteria on periapical tissue healing after chemomechanical treatment and root filling of experimentally infected monkey teeth. *Eur J Oral Sci.* 2006; 114: 278–285.
- Hülsmann M, Peters OA, Dummer PMH Mechanical preparation of root canals: shaping goals, techniques and means. *Endodontic Topics*, 2005 (10), 30–76.